



Contents lists available at ScienceDirect

The Journal of Arthroplasty

journal homepage: www.arthroplastyjournal.org



Basic Science

Customized versus Patient-Sized Cruciate-Retaining Total Knee Arthroplasty: An In Vivo Kinematics Study Using Mobile Fluoroscopy



Ian M. Zeller, MS^{a,*}, Adrija Sharma, PhD^a, William B. Kurtz, MD^b,
Mathew R. Anderle, BS^a, Richard D. Komistek, PhD^a

^a Center for Musculoskeletal Research, MABE Department, University of Tennessee, Knoxville, Tennessee

^b Department of Orthopedic Surgery, St. Thomas-Midtown Hospital, Tennessee Orthopedic Alliance, Nashville, Tennessee

ARTICLE INFO

Article history:

Received 12 April 2016

Received in revised form

22 September 2016

Accepted 26 September 2016

Available online 4 October 2016

Keywords:

TKA

customized TKA

cruciate-retaining

posterior stabilized

kinematics

mobile fluoroscopy

ABSTRACT

Background: Historically, knee arthroplasties have been designed using average patient anatomy. Recent advances in imaging and manufacturing have facilitated the development of customized prostheses designed to fit the unique shape of individual patients. The purpose of this study is to determine if improving implant design through customized total knee arthroplasty (TKA) improves kinematic function.

Methods: Using state-of-the-art mobile fluoroscopy, tibiofemoral kinematics were analyzed for 24 subjects with a customized individually made (CIM), cruciate-retaining TKA, and 14 subjects having an asymmetric condylar cruciate-retaining TKA. Subjects performed a weight-bearing deep knee bend and a rise from a seated position. Each patient was evaluated for weight-bearing range of motion, femorotibial translation, femorotibial axial rotation, and condylar liftoff occurrence.

Results: Subjects having a CIM TKA experienced greater weight-bearing knee flexion compared with the traditional posterior cruciate-retaining (PCR) TKA design. During flexion, the CIM TKA subjects consistently exhibited more posterior femoral rollback than the traditional PCR TKA subjects. The CIM TKA was found to have statistically greater axial rotation compared with the traditional PCR TKA ($P = .05$). Of note, only the CIM TKA patients experienced femoral internal rotation at full extension, as exhibited in a normal knee. Compared with the traditional PCR TKA, the CIM TKAs demonstrated minimal occurrences of paradoxical sliding and reverse rotation during flexion and extension. The CIM TKA subjects showed minimal liftoff and hence better stability in earlyflexion to midflexion compared with the traditional PCR subjects.

Conclusion: The CIM TKA demonstrated kinematics more similar to a normal knee. Therefore, using customized implant technology through CIM TKA designs affords benefits including more normal motion compared with a traditional PCR TKA.

© 2016 Elsevier Inc. All rights reserved.

Traditional total knee arthroplasty (TKA) has been a highly successful procedure with respect to the restoration of basic function for late-stage arthritis patients, substantially increasing quality of life. Although implant survivorship has been excellent, reported patient satisfaction has lagged substantially behind other orthopedics procedures such as total hip arthroplasty, with upward of 20% of TKA patients reporting dissatisfaction with regard to implant outcomes [1–5]. There are a number of reasons why such a large

subset of patients report dissatisfied outcomes and the three most recurring reported factors tend to be pain, stiffness, and limited function [1,6]. It is believed that demographic factors such as age, gender, and body mass index can also be influential factors with respect to patient outcomes [2–13].

A properly functioning TKA tends to assuage the most common criticisms regarding pain and stiffness, and for this reason has led to the belief that a TKA should restore “normal-like” kinematic function. Although many implants currently on the market perform well, they still fall short in successfully achieving the kinematics of normal knee [14].

Every patient has a unique anatomical geometry and these geometries can vary because of gender, ethnicity, and body type between patients [15–20]. There is also substantial variation between individual subjects within these groups, suggesting that a customized implant may be advantageous compared with ethnic

One or more of the authors of this paper have disclosed potential or pertinent conflicts of interest, which may include receipt of payment, either direct or indirect, institutional support, or association with an entity in the biomedical field which may be perceived to have potential conflict of interest with this work. For full disclosure statements refer to <http://dx.doi.org/10.1016/j.arth.2016.09.034>.

* Reprint requests: Ian M. Zeller, MS, Center for Musculoskeletal Research, MABE Department, University of Tennessee, 310 Perkins Hall, Knoxville, TN 37996.

<http://dx.doi.org/10.1016/j.arth.2016.09.034>

0883-5403/© 2016 Elsevier Inc. All rights reserved.

Table 1
Summary of Subject Demographics for Both Groups Within the Study.

	CIM TKA				PCR TKA			
	Average	Min	Max	SD	Average	Min	Max	SD
Age, y	60.2	43.0	71.3	7.7	66.7 ^a	57.0	78.0	5.7
Postoperative, mo	9.6	6.6	17.4	3.2	13.3 ^a	7.5	29	5.6
BMI, kg/m ²	30.8	23.7	38.9	5.6	32.4	28.5	41.6	4.3

BMI, body mass index; CIM, customized individually made; PCR, posterior cruciate-retaining; SD, standard deviation; TKA, total knee arthroplasty.

^a Statistically significant difference from CIM group ($P < .05$).

and/or gender-specific TKA [17]. Initially, patients receiving a customized TKA undergo a computerized tomography scan, which is used to design individualized implant components that match the anatomy of the tibial plateau and femoral condylar geometries of each patient, while simultaneously achieving a neutral mechanical axis [21–23]. These implants have shown success at replicating normal knee kinematics in vitro [24], but there is currently no research evaluating these implants in vivo.

The purpose of this study is to determine and compare the in vivo kinematics of a customized posterior cruciate-retaining (PCR) TKA when compared with a traditional PCR TKA in order to determine what kinematic differences exist between these two implant types, and whether improving the shape of an implant using a customized methodology contributes to improved kinematic function. This data will then be further compared the results with normal knee data previously reported in the literature. In addition, this is one of the first studies to use a state-of-the-art mobile fluoroscopy unit—which captures higher quality images, while consistently keeping the knee joint in the center of the fluoroscopic field-of-view—in order to compare the kinematics of both implant types to determine what kinematic differences exist between them. It was hypothesized that improving implant component design using a customized TKA philosophy, will allow for more normal kinematics than the subjects having a traditional TKA.

Methods

Patient Demographics

This study was conducted using 38 subjects. Twenty-four subjects were implanted with a customized individually made (CIM) iTotal PCR TKA (ConforMIS Inc, Bedford, MA), and 14 subjects were

implanted with a NexGen high-flexion traditional PCR TKA (Zimmer Biomet Inc, Warsaw, IN). This is a single surgeon series and all patients had been diagnosed with progressive osteoarthritis. The chosen surgeon in this study has more experience implanting the traditional TKA and more recently began using the customized TKA. Patients were all deemed to have excellent clinical performance as assessed by Knee Society Scores (≥ 90) with no ligament laxity or pain presented at a minimum 6-month postoperative time. The subjects were evaluated for age, body mass index, and postoperative time between the two groups (Table 1). When compared with the CIM group, the traditional PCR group had a statistically significant higher average age and longer postoperative evaluation time. Before the data collection, all patients completed the informed consent paperwork as required by the institutional review board.

Kinematic Analysis

Patients were asked to perform two activities under fluoroscopic surveillance in the sagittal plane using a mobile fluoroscopic unit. Unlike the traditional static C-arms, where the patient moves but the unit is stationary, the mobile fluoroscopy unit has a control system that allows the image intensifier to automatically follow the subject and constantly keep the joint of interest centered in the field-of-view. This unit leads to higher resolution (blur and occlusion free) images, and more importantly allows patients to perform activities in an unhindered manner; thus providing a more natural representation of dynamic activities. The activities performed by the subject were (1) a weight-bearing deep knee bend (DKB) and (2) a chair rise (Fig. 1). Subjects were asked to perform the DKB without the assistance of handrails or other supports at a speed with which they felt most comfortable.

The fluoroscopic videos of each activity were then digitized and kinematic analysis was performed from the fluoroscopic images using a 3D to 2D image registration technique at full extension, maximum flexion, and at 30° increments throughout the flexion cycle [25,26]. This technique registers computer-aided design (CAD) models on the silhouettes of the fluoroscopic images (Fig. 2) in order to obtain transformation matrices of the computer-aided design models oriented in the image space. The entire process has previously been validated and error measurements are less than 0.5° and 0.5 mm for in plane rotations and translations, respectively [25] (Fig. 3).

Although the polyethylene bearing is radiolucent in fluoroscopic images and the implants studied are of fixed bearing type, it was



Fig. 1. Subjects performing a deep knee bend (DKB) (top), chair rise (bottom), while under fluoroscopic surveillance with the mobile fluoroscopic unit.

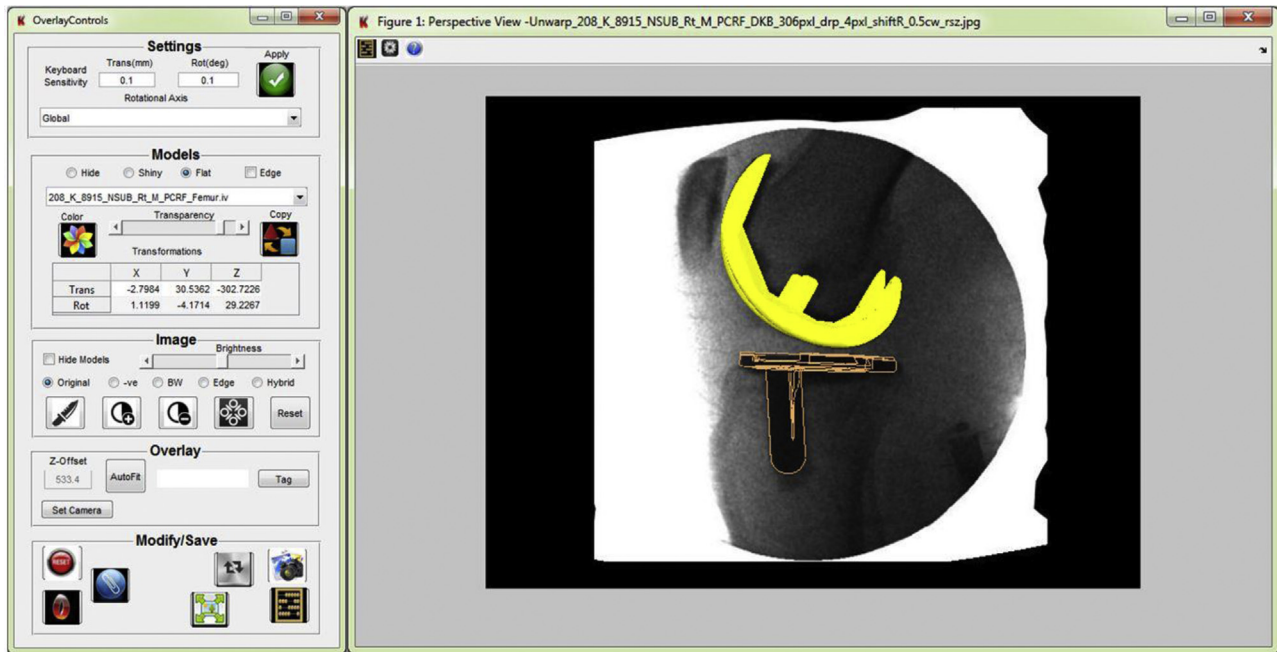


Fig. 2. Example of the 3D to 2D image registration interface.

assumed that the bearing was rigidly connected to the tibial component. Using transformation matrices obtained from the registered image sequence, the kinematics of the femoral component with respect to tibia and/or bearing component were extracted and used for analysis of implant motion. The origin of the tibia coordinate system was set at the geometric center (obtained at the intersection of the main diagonals of the bounding box containing the tibial component; Fig. 4). The translation and rotational kinematics of the femur were analyzed by tracking the lowest point on the femoral lateral and medial condyles with respect to the tibia in the coronal plane. The specific measurements of interest included the lateral anterior/posterior (LAP) position, the medial anterior/posterior (MAP) position, and axial orientation (obtained as the

angle formed by the line joining LAP and MAP with the medio-lateral axis of the tibia) of the femur with respect to the tibia. LAP and MAP values are denoted as positive if they occur anterior to the tibial origin and are denoted as negative if they occur posteriorly to the tibial origin (Fig. 4). Axial orientation is denoted as positive if the femur is externally rotated with respect to the tibia and negative if the femur is internally rotated. Translation and axial rotation values were obtained as the difference of position or axial orientation values between two individual instances of the activity.

Contact maps between the femoral and polyethylene components were then calculated to identify contact points (assumed to be the centroid of the area in contact). Any distance below the error tolerance of the fluoroscopic process was assumed to be in contact

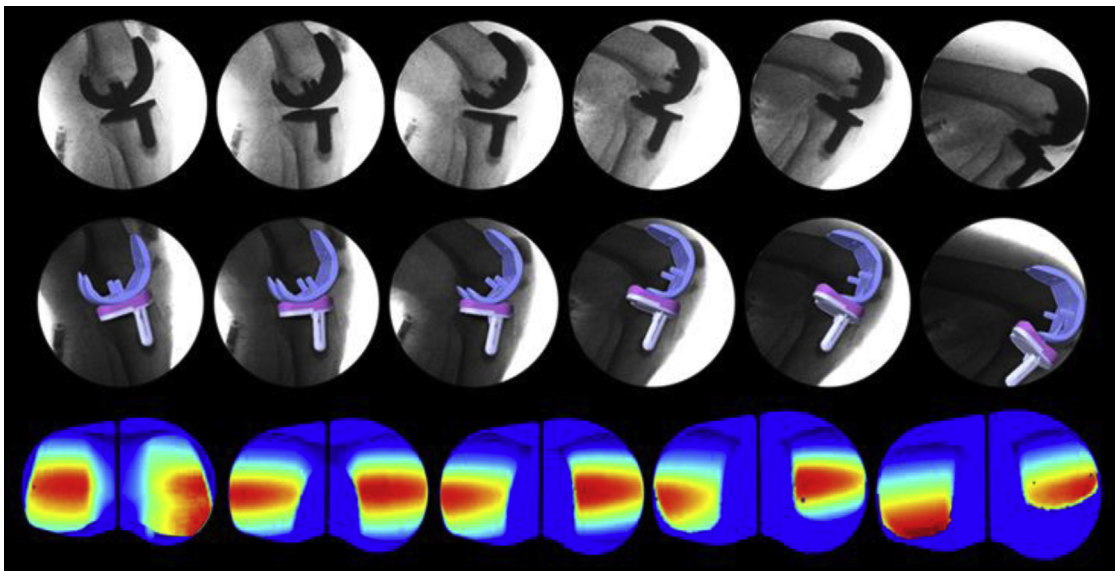


Fig. 3. Fluoroscopic image sequence for DKB from full extension to maximum flexion at 30° increments (top), and the same images with the respective computer-aided design (CAD) models overlaid after completion of the 3D to 2D image registration process (middle) and calculated contact maps (bottom).

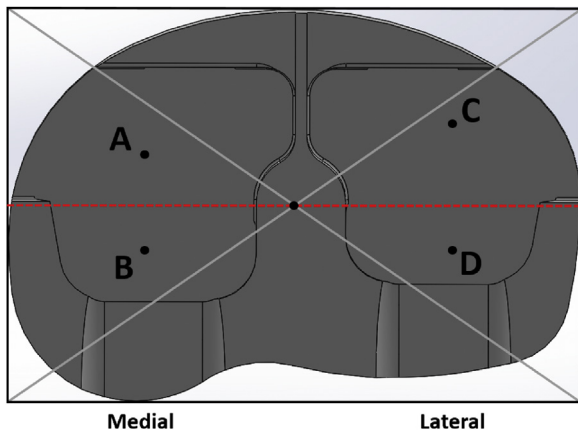


Fig. 4. Anterior/posterior (AP) points for a right knee as measured by 3D to 2D image registration process. Points A and C are defined as positive AP positions, whereas B and D are defined as negative AP positions. A translation from a positive point to a negative point is denoted as a negative translation. If a medial anterior/posterior (MAP) point is more anterior than the lateral anterior/posterior (LAP) point, such as points A and D, the angular orientation is positive. A pivot from point C to D about point A is an example of positive axial rotation.

and any distance greater than 1 mm between the polyethylene and femur contact points was considered to be condylar liftoff.

Statistical Analysis

Statistical analyses were carried out at 95% confidence level ($\alpha = 0.05$) using IBM SPSS (SPSS software, IBM, Armonk, NY) software. Samples were tested for variance between groups, and a two tailed *t* test of significance for independent samples of heteroscedastic distributions was carried out to identify statistically significant differences between the means of the two implanted groups. For categorical variables, a contingency analysis using Fisher exact test was carried out. These results were then compared

Table 2
Range of Motion, Condyle Translation, Axial Rotation, and Condyle Liftoff Results Between CIM (Customized Individually Made) and OTS (Off the Shelf) Implant Designs During Deep Knee Bend From Full Extension to Maximum Flexion.

	iTotal CIM	Nexgen PCR
Range of motion (°)	103.8 ± 14.7	95.8 ± 21.2
Medial condylar translations		
Average contact at full extension, mm	-4.0 ± 1.5	-3.0 ± 1.6
Average contact at full flexion, mm	-2.5 ± 2.5	-0.8 ± 3.2
Average femoral translation (+anterior, -posterior), mm (full extension to maximum flexion)	1.4 ± 2.6	2.2 ± 2.8
Lateral condylar translations		
Average contact at full extension, mm	-3.8 ± 2.8	-8.9 ± 4.4
Average contact at full flexion, mm	-7.8 ± 5.2	-10.1 ± 4.2
Average femoral translation (+anterior, -posterior), mm (full extension to maximum flexion)	-4.0 ± 4.9 ^a	-1.2 ± 3.9
Axial rotation		
Axial orientation at full extension (°)	-0.3 ± 3.4 ^a	7.4 ± 5.3
Axial orientation at maximum flexion (°)	6.0 ± 6.2	11.8 ± 4.9
Axial rotation (+external, -internal) (°) (full extension to maximum flexion)	6.3 ± 5.9 ^a	4.4 ± 5.8
Condyle liftoff		
Early flexion (<60°) medial and lateral liftoff, %	0 ^a	35.7
Late flexion (≥60°) medial and lateral liftoff, %	25.0	14.3

CIM, customized individually made; PCR, posterior cruciate-retaining.

^a Statistically significant difference from Nexgen PCR (OTS) group ($P \leq .05$).

between the CIM and PCR TKA groups to determine differences between implant kinematics and ultimately determine which implant had more normal kinematic patterns.

Results

Deep Knee Bend

During the DKB activity, the average maximum flexion was higher for the CIM TKA (103.8°) compared with the traditional PCR (95.8°) ($P = .228$; Table 2). On average, from full extension to maximum knee flexion, the CIM patients (-4.0 mm) experienced significantly higher amounts of posterior femoral translation (femoral rollback) of the lateral condyle than the traditional PCR group patients (-1.2 mm; $P = .046$). Twenty-one of 24 (88%) CIM and 9 of 14 (64%) traditional PCR subjects exhibited posterior lateral motion, consistent with normal knee motion. The medial condyle translations were statistically similar for both groups (Table 2) with 18 of 24 (75%) CIM and 10 of 14 (71%) traditional PCR patients exhibiting anterior motion of the medial condyle from full extension to maximum flexion (Fig. 5).

On average, from full extension to maximum flexion, the CIM and the traditional PCR groups experienced 6.3 and 4.4 degrees of axial rotation, respectively (Table 2) with 3 of 24 (13%) CIM TKAs and 4 of 14 (29%) PCR TKAs demonstrating instances of reverse axial rotation (internal rotation of the femur with respect to the tibia) (Fig. 6A). Interestingly, the CIM TKA experienced femoral internal orientation at full extension, as exhibited in the normal knee, shifting to femoral external rotation with progressive knee flexion. The traditional PCR TKA experienced femoral external rotation at each flexion increment, inconsistent with normal knee motion. At full extension, the CIM and the traditional PCR TKA experienced -0.3 and 7.4 ($P < .0001$) degrees of femoral rotational orientation, respectively, relative to the neutral orientation.

Contact map analysis revealed that from full extension to full flexion, there were instances of condylar liftoff greater than 1 mm of the medial condyle in 6 of 24 (25%) CIM subjects. None of the CIM subjects demonstrated liftoff of the lateral condyle. For the traditional PCR TKA subjects, 5 of 14 (36%) and 3 of 14 (21%) demonstrated instances of liftoff for the lateral and medial condyles, respectively (Fig. 7). Although both CIM and PCR implants demonstrated liftoff during the DKB activity, 35% of PCR patients

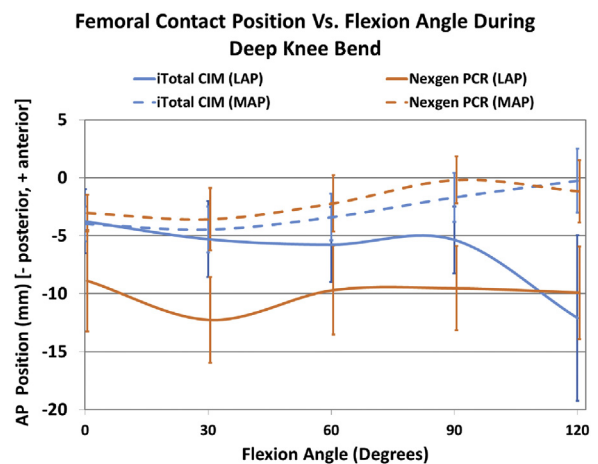


Fig. 5. Average A-P contact positions for subjects implanted with CIM or traditional total knee arthroplasty (TKA). Information is also displayed graphically. CIM, customized individually made; LAP, lateral anterior/posterior; MAP, medial anterior/posterior; PCR, posterior cruciate-retaining.

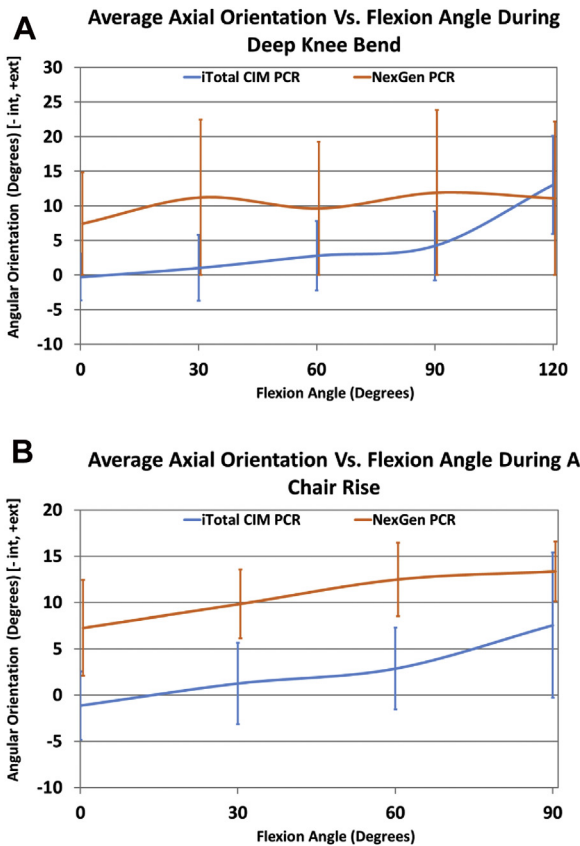


Fig. 6. (A) Comparison of average tibiofemoral axial orientation during a DKB. (B) Comparison of average tibiofemoral axial orientation during chair rise.

demonstrated at least one incident of liftoff before 60 degrees of flexion. All the CIM TKAs that demonstrated liftoff did so in deeper flexion.

Chair Rise

On average, from a seated position (90 degrees of flexion) to full extension, the CIM and the traditional PCR groups experienced 2.5 and 0.2 mm ($P = .05$) of lateral roll forward (anterior translation) motion during the chair rise, respectively. Twenty-one of 24 (88%) subjects in the CIM TKA group exhibited a roll forward motion of the lateral condyle compared with 9 of 14

(64%) patients in the traditional PCR TKA group. With respect to the translation of the medial condyle 22 of 24 (92%) CIM patients and 12 of 14 (86%) traditional patients exhibited posterior motion of the medial condyle. Both groups were statistically similar with respect to translation of the medial condyle, whereas the magnitude of translation of the lateral condyle for the traditional PCR TKA design was statistically smaller than the CIM TKA group ($P = .05$; Table 3).

On average, from the seated position to the standing position subjects having a CIM and traditional PCR TKA experienced -7.1 and -4.8 degrees of axial rotation, respectively, with 2 of 24 (8%) CIM TKAs and 4 of 14 (29%) PCR TKAs exhibiting reverse axial rotation (external rotation of the femur with respect to the tibia). The CIM TKA was found to have statistically greater axial rotation compared with the traditional PCR TKA ($P = .05$; Fig. 6B).

Discussion

This is the first study to determine the in vivo kinematics for subjects implanted with a customized TKA and one of the first studies using a mobile fluoroscopy unit. The CIM implant experienced statistically greater lateral femoral condyle anterior/posterior (AP) motion and axial rotation compared with the traditional PCR TKA during both a DKB and a chair rise. On average, the CIM TKA demonstrated kinematic patterns consistent with those of the normal knee, but with less overall magnitude [14,16,27].

The authors acknowledge that there are limitations associated with this study as well. There is not a normal control for this study although the motions of the normal knee are well understood in literature and are consistent between various studies conducted to investigate normal knee motion. This study also did not include preoperative assessment to contextualize postoperative range of motion; therefore, clinical significance comparing the postoperative range of motion between two groups is limited. Although there were statistically significant differences within the data, the number of patients included in the study was small and more confident comparisons could be drawn from larger patient groups. The nature of these intensive studies generally leads to study groups that are relatively small, the group sizes are comparable with other studies published in literature [27–32] using a similar methodology. The postoperative times are also relatively short; however, previously published studies had shown sufficient amount of time for postoperative recovery [32]. Furthermore, studies conducted on implants at various time points postsurgery have shown that in vivo kinematics over the entire range of motion

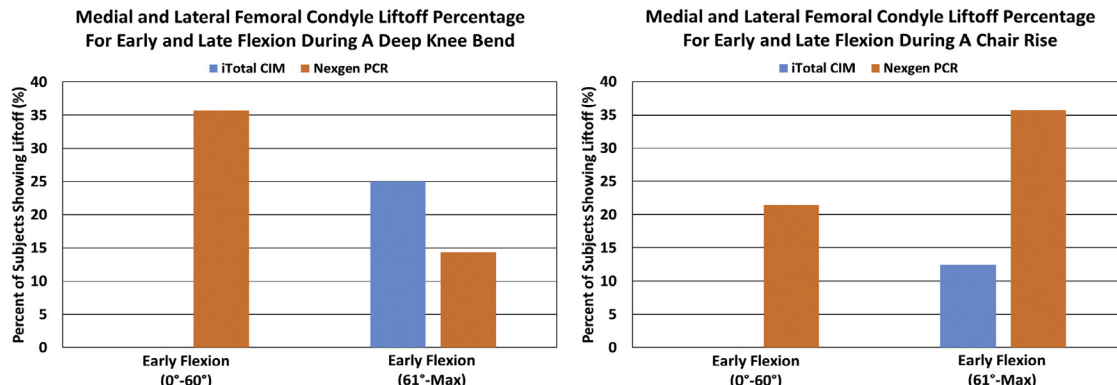


Fig. 7. Percentage of patients showing at least 1 mm of condylar liftoff during a DKB and chair rise activity between 0 and 60 degrees of flexion in addition to liftoff greater than 1 mm occurring at greater than 60 degrees of flexion. CIM denotes customized, individually made and OTS denotes off the shelf (traditional) design.

Table 3

Condyle Translation, Axial Rotation, and Condyle Liftoff Results Between CIM (Customized Individually Made) and OTS (Off the Shelf) Implant Designs During Chair Rise From 90° Flexion to Full Extension.

	iTotal CIM	Nexgen PCR
Medial condylar translations		
Average contact at full extension, mm	0.1 ± 3.1	0.8 ± 3.5
Average contact at full flexion, mm	-3.8 ± 3.4	-2.8 ± 1.8
Average femoral translation (+anterior, -posterior), mm (90° to full extension)	3.8 ± 1.8	3.6 ± 3.7
Lateral condylar translations		
Average contact at full extension, mm	-5.2 ± 3.2	-8.6 ± 3.3
Average contact at full flexion, mm	-2.7 ± 3.0	-8.4 ± 4.1
Average femoral translation (+anterior, -posterior), mm (90° to full extension)	2.5 ± 3.0 ^a	0.2 ± 3.5
Axial rotation		
Axial orientation at full extension (°)	6.0 ± 6.2	12.0 ± 4.4
Axial orientation at maximum flexion (°)	-1.15 ± 3.7	7.3 ± 5.1
Axial rotation (+external, -internal) (°) (90° to full extension)	-7.13 ± 5.4 ^a	-4.75 ± 6.7
Condyle liftoff		
Early flexion (<60°) medial and lateral liftoff, %	0 ^a	21.4
Late flexion (≥60°) medial and lateral liftoff, %	12.5	35.7

CIM, customized individually made; PCR, posterior cruciate-retaining.

^a Statistically significant difference from Nexgen PCR (OTS) group ($P < .05$).

do not change significantly with time [30] especially over longer postoperative times.

Although there were some statistically significant differences in the patient demographics, the traditional PCR group average age was older and the CIM group had a shorter postoperative time. Because patient age tends to affect TKA performance inversely and postoperative time tends to influence overall TKA performance directly over the short term (less than a year) after the TKA procedure, we believe that the two factors play an offsetting role allowing for a reasonable comparison between the two groups. Also, the chosen surgeon in this study had greater experience implanting the traditional PCR TKA compared with the CIM TKA. There are a number of variables built into any research study in orthopedics; however, by using a single surgeon and maintaining inclusion criteria to recruit successful TKA patients (Knee Society Scores >90), it is possible to limit confounding variables in the study. Although there were limitations, it is deemed from our previous experience conducting fluoroscopic studies that the use of mobile fluoroscopy is an advancement and the limitations cited would not lessen the validity of the data and/or the findings.

Previous studies conducted by Komistek et al [27] have reported that the lateral femoral condyle of the normal knee

exhibits an average of -14.1 mm of PFR and the medial condyle exhibited an average of -1.5 mm of PFR from full extension to 90 degrees of knee flexion in vivo. In a follow-up study, they documented that the lateral condyle can roll in the posterior direction up to 28.0 mm and the medial condyle up to 10.0 mm from full extension to maximum knee flexion [22]. This motion leads to the femur experiencing up to 8.0 degrees of femoral internal rotation at full extension and upward of 20 degrees of femoral external rotation with respect to the tibia at maximum knee flexion [22]. Multiple studies also documented that, although the medial condyle exhibits a net posterior motion from full extension to maximum flexion, after midflexion (approximately 70°), the average medial condyle translates anteriorly through maximum flexion [14,27]. The asymmetrical motion pattern of the femoral condyles facilitates an external axial rotation of the femur with respect to the tibia. Dennis et al reported an average magnitude of rotation to be 23.67° [14].

Compared with normal knee kinematics during a DKB, traditional PCR TKAs generally exhibit consistent instances of paradoxical anterior slide and reverse rotation of the femoral component with increasing flexion [28,33-35]. This motion pattern is believed to be because of the absence of the anterior cruciate ligament [14,27,36], the inability to balance the posterior cruciate ligament properly with the absence of the counterbalance of the anterior cruciate ligament [37-39], and account for the changed geometry of the implanted knee.

In this present study, 88% of subjects having a CIM TKA demonstrated posterior femoral translation, whereas only 64% of traditional PCR subjects exhibited a posterior motion. This finding is consistent with literature on traditional PCR TKAs [26,27,29,35]. Although the CIM TKA is a PCR design, subjects having this TKA design experienced femoral translation magnitudes similar to the normal knee, noted with a larger lateral posterior translation and a minimal medial translation, although less in magnitude. Because the medial translation was found to be similar between the groups, the difference in translation of the lateral condyle—significantly higher for the CIM group (Fig. 8)—accounts for differences in the axial rotation patterns of both implants. In addition, the CIM results compare well with past in vitro studies, which showed that CIM implants can better approximate normal knee motion. Lastly, these results were also similar during flexion to extension (chair rise) except that kinematic patterns were reversed validating that flexion of the knee occurs as a reversible process.

The CIM TKA subjects did experience a transition from internal femoral rotation at full extension to femoral external rotation with increasing knee flexion, whereas subjects having a traditional PCR TKA experienced external rotation of their femur with respect to the tibia throughout all flexion angles. This is likely due to the external rotation required in traditional TKA during the implantation process to close the lateral flexion gap. Because the CIM TKA maintains the distal and posterior femoral offset, external rotation is not required during implantation, thus originating the femoral component in a more neutral, normal rotational alignment.

Condylar liftoff greater than 1 mm was observed in both groups for at least one of the activities. Although both CIM and PCR implants demonstrated liftoff, during the DKB activity, 35% of the traditional PCR patients demonstrated at least one instance of liftoff before 60 degrees of flexion. All the CIM TKAs that demonstrated liftoff did so in deeper flexion, a pattern that is similar to that of the normal knee where liftoff tends to be more prevalent in deeper flexion [40]. This demonstrates improved midflexion stability of the CIM TKA compared with the PCR design. One reason for this could be the ability of the CIM implant to recreate patient's sagittal J-curves with




Fig. 8. Axial rotations of femur relative to the respective tibia for a PCR TKA (top row) and CIM TKA (bottom row) during a DKB. The left images are at full extension and the right images are at full flexion. The red polygon represents the bounding region between the original medial and lateral contact points at full extension and the final medial and lateral contact points at 30° increments.

better accuracy when compared with the traditional PCR TKA, leading to a higher likelihood of a stable knee in midflexion.

Conclusions

In conclusion, this is one of the first studies to determine in vivo kinematics of a CIM implant with a mobile fluoroscopy unit tracking patients, allowing them to perform activities in unrestricted, normal fashion. Similar to previous studies, neither design was able to replicate the translation and rotation magnitudes of the normal knee. However, CIM TKA patients did exhibit patterns that were more consistent with the normal knee than the traditional PCR counterparts (Fig. 8). The authors postulate that for the CIM TKA, the customized nature of the implant shape facilitates improved translation and rotation properties compared with traditional PCR TKAs.

Acknowledgments

The authors would like to thank ConforMIS for research support for this study.

References

- Mannion AF, Kämpfen S, Munzinger U, et al. The role of patient expectations in predicting outcome after total knee arthroplasty. *Arthritis Res Ther* 2009;11:R139.
- Anderson JG, Wixson RL, Tsai D, et al. Functional outcome and patient satisfaction in total knee patients over the age of 75. *J Arthroplasty* 1996;11:831.
- Baker P, Van der Meulen J, Lewsey J, et al. The role of pain and function in determining patient satisfaction after total knee replacement. Data from the National Joint Registry for England and Wales. *J Bone Joint Surg Br* 2007;89:893.
- Baumann C, Rat AC, Mainard D, et al. Importance of patient satisfaction with care in predicting osteoarthritis-specific health-related quality of life one year after total joint arthroplasty. *Qual Life Res* 2011;20:1581.
- Bourne RB, McCalden RW, MacDonald SJ, et al. Influence of patient factors on TKA outcomes at 5 to 11 years followup. *Clin Orthop Relat Res* 2007;464:27.
- Bourne RB, Chesworth BM, Davis AM, et al. Patient satisfaction after total knee arthroplasty: who is satisfied and who is not? *Clin Orthop Relat Res* 2010;468:57.
- Bullens PH, van Loon CJ, de Waal Malefijt MC, et al. Patient satisfaction after total knee arthroplasty: a comparison between subjective and objective outcome assessments. *J Arthroplasty* 2001;16:740.
- Clement N, Burnett R. Patient satisfaction after total knee arthroplasty is affected by their general physical well-being. *Knee Surg Sports Traumatol Arthrosc* 2013;21:2638.
- Devers BN, Conditt MA, Jamieson ML, et al. Does greater knee flexion increase patient function and satisfaction after total knee arthroplasty? *J Arthroplasty* 2011;26:178.
- Gandhi R, Dhotar H, Razak F, et al. Predicting the longer term outcomes of total knee arthroplasty. *Knee* 2010;17:15.
- Jacobs CA, Christensen CP. Factors influencing patient satisfaction two to five years after primary total knee arthroplasty. *J Arthroplasty* 2014;29:1189.
- Merle-Vincent F, Couris CM, Schott AM, et al. Factors predicting patient satisfaction 2 years after total knee arthroplasty for osteoarthritis. *Joint Bone Spine* 2011;78:383.
- Noble PC, Conditt MA, Cook KF, et al. The John Insall Award: patient expectations affect satisfaction with total knee arthroplasty. *Clin Orthop Relat Res* 2006;452:35.
- Dennis DA, Komistek RD, Mahfouz MR, et al. Coventry Award Paper: multi-center determination of in vivo kinematics after total knee arthroplasty. *Clin Orthop Relat Res* 2003;416:37.
- Guy S, Farndon M, Sidhom S, et al. Gender differences in distal femoral morphology and the role of gender specific implants in total knee replacement: a prospective clinical study. *Knee* 2012;19:28.
- Leszko F, Hovinga KR, Lerner AL, et al. In vivo normal knee kinematics: is ethnicity or gender an influencing factor? *Clin Orthop Relat Res* 2011;469:95.
- van den Heever DJ, Scheffer C, Erasmus P, et al. Classification of gender and race in the distal femur using self organising maps. *Knee* 2012;19:488.
- Parsley BS, Bertolusso R, Harrington M, et al. Influence of gender on age of treatment with TKA and functional outcome. *Clin Orthop Relat Res* 2010;468:1759.
- Bellemans J, Carpentier K, Vandenuecker H, et al. The John Insall Award: both morphotype and gender influence the shape of the knee in patients undergoing TKA. *Clin Orthop Relat Res* 2010;468:29.
- Li P, Tsai TY, Li JS, et al. Gender analysis of the anterior femoral condyle geometry of the knee. *Knee* 2014;21:529.
- Wong T, Slamin J, Lang P. *Patient-specific and patient-engineered orthopedic implants*. United States Patent Application US12965493. Alexandria VA: US Patent and Trademark office Location; 2011.
- Palumbo BT, Lindsey J, Fitz W. Patient-specific total knee arthroplasty: a novel technique and implant. *Tech Knee Surg* 2012;11:182.
- O'Connor MI, Kransdorf MJ. Customized knee arthroplasty and the role of preoperative imaging. *Am J Roentgenol* 2013;201:W443.
- Patil S, Bunn A, Bugbee WD, et al. Patient-specific implants with custom cutting blocks better approximate natural knee kinematics than standard TKA without custom cutting blocks. *Knee* 2015;22:624.
- Mahfouz MR, Hoff W, Komistek RD, et al. A robust method for registration of three-dimensional knee implant models to two-dimensional fluoroscopy images. *IEEE Trans Med Imaging* 2003;22:1561.
- Bertin KC, Komistek RD, Dennis DA, et al. In vivo determination of posterior femoral rollback for subjects having a NexGen posterior cruciate-retaining total knee arthroplasty. *J Arthroplasty* 2002;17:1040.
- Komistek RD, Dennis DA, Mahfouz M. In vivo fluoroscopic analysis of the normal human knee. *Clin Orthop Relat Res* 2003;410:69.
- Cates HE, Komistek RD, Mahfouz MR, et al. In vivo comparison of knee kinematics for subjects having either a posterior stabilized or cruciate retaining high-flexion total knee arthroplasty. *J Arthroplasty* 2008;23:1057.
- Nakamura S, Ito H, Kobayashi M, et al. Are the long term results of a high-flex total knee replacement affected by the range of flexion? *Int Orthop* 2014;38:761.
- LaCour MT, Sharma A, Carr CB, et al. Confirmation of long-term in vivo bearing mobility in eight rotating-platform TKAs. *Clin Orthop Relat Res* 2014;472:2766.
- Zingde SM, Leszko F, Sharma A, et al. In vivo determination of cam-post engagement in fixed and mobile-bearing TKA. *Clin Orthop Relat Res* 2014;472:254.
- Grieco TF, Sharma A, Komistek RD, et al. Single versus multiple-radii cruciate-retaining total knee arthroplasty: an in vivo mobile fluoroscopy study. *J Arthroplasty* 2016;31:694.
- Yoshiya S, Matsui N, Komistek RD, et al. In vivo kinematic comparison of posterior cruciate-retaining and posterior stabilized total knee arthroplasties under passive and weight-bearing conditions. *J Arthroplasty* 2005;20:777.
- Tanzer M, Smith K, Burnett S. Posterior-stabilized versus cruciate-retaining total knee arthroplasty: balancing the gap. *J Arthroplasty* 2002;17:813.
- Maruyama S, Yoshiya S, Matsui N, et al. Functional comparison of posterior cruciate-retaining versus posterior stabilized total knee arthroplasty. *J Arthroplasty* 2004;19:349.
- Horiuchi H, Akizuki S, Tomita T, et al. In vivo kinematic analysis of cruciate-retaining total knee arthroplasty during weight-bearing and non-weight-bearing deep knee bending. *J Arthroplasty* 2012;27:1196.
- Conditt MA, Noble PC, Bertolusso R, et al. The PCL significantly affects the functional outcome of total knee arthroplasty. *J Arthroplasty* 2004;19:107.
- Li E, Ritter MA. The case for retention of the posterior cruciate ligament. *J Arthroplasty* 1995;10:560.
- Yue B, Varadarajan KM, Moynihan AL, et al. Kinematics of medial osteoarthritic knees before and after posterior cruciate ligament retaining total knee arthroplasty. *J Orthop Res* 2011;29:40.
- Dennis D, Komistek R, Walker S, et al. Femoral condylar lift-off in vivo in total knee arthroplasty. *J Bone Joint Surg Br* 2001;83:33.